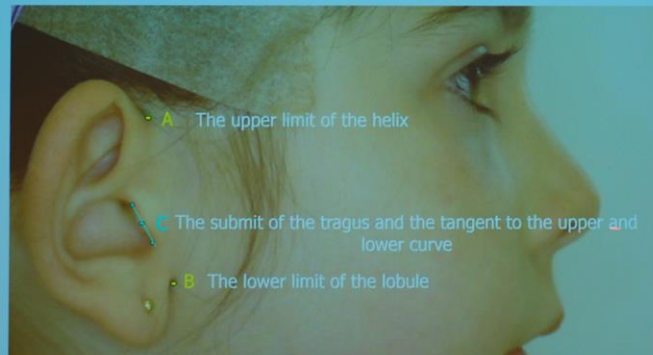
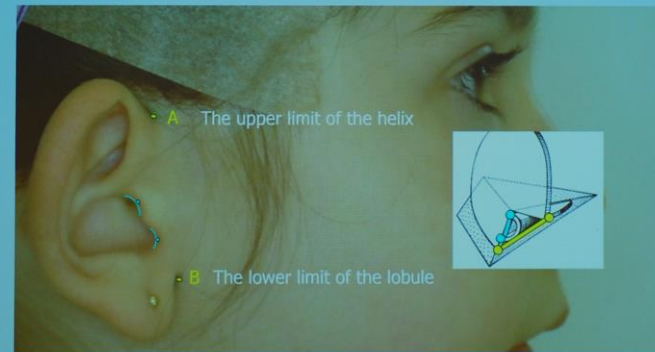
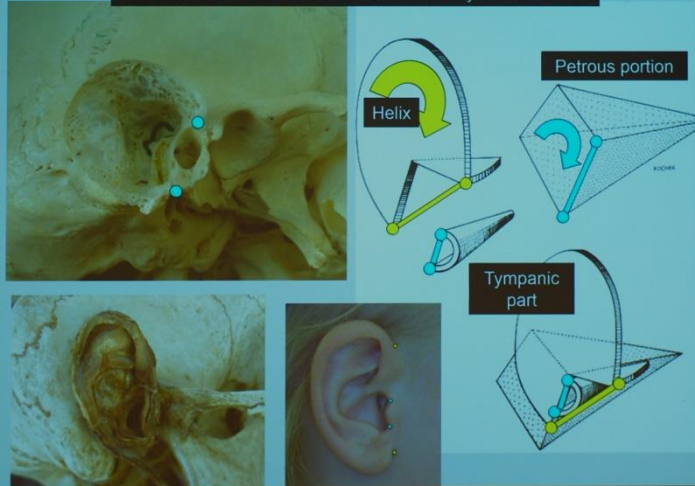


To sum up: drawing ears' axes

Cutaneous landmarks related to the bony structures



Two cutaneous landmarks noted before taking the photo

